

# COBB ANGLE IS NOT ALWAYS EQUAL TO THE BODY SYMMETRY ON THE COSMETIC ASPECT OF SCOLIOSIS.

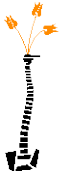Chin-Yi CHUO, Wun-Jer SHEN\* , Young-Shung SHEN\*  
Kaohsiung Municipal Hsiao-Kang Hospital Kaohsiung, Taiwan  
Po-Cheng Orthopaedic Institute, Kaohsiung, Taiwan\*



SPINEWEEK 2012 RAI AMSTERDAM 28 MAY - 1 JUNE



- Conflict of interest: No conflicting interest declared.



# With Idiopathic Scoliosis ...

- Neurologic deficits are very rare
  - Syrinx, congenital
- Respiratory deficits are not seen till thoracic curve  $>90^\circ$
- Pain is unusual till onset of DJD
  - Pre-emptive fusion, stress transfer
- **For most cases- We are correcting the deformity. So it is a cosmetic surgery**

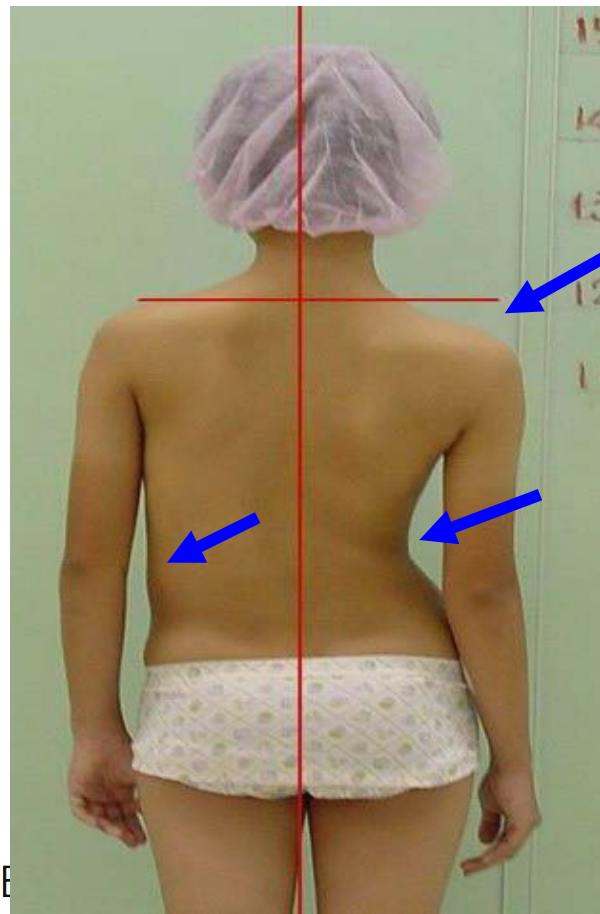
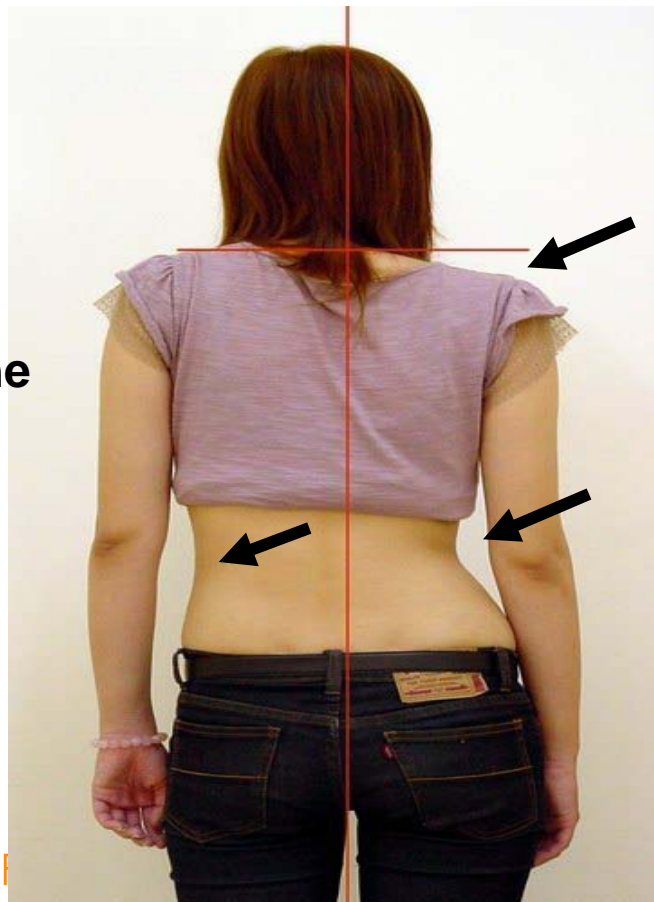


# A Tale of Two Women

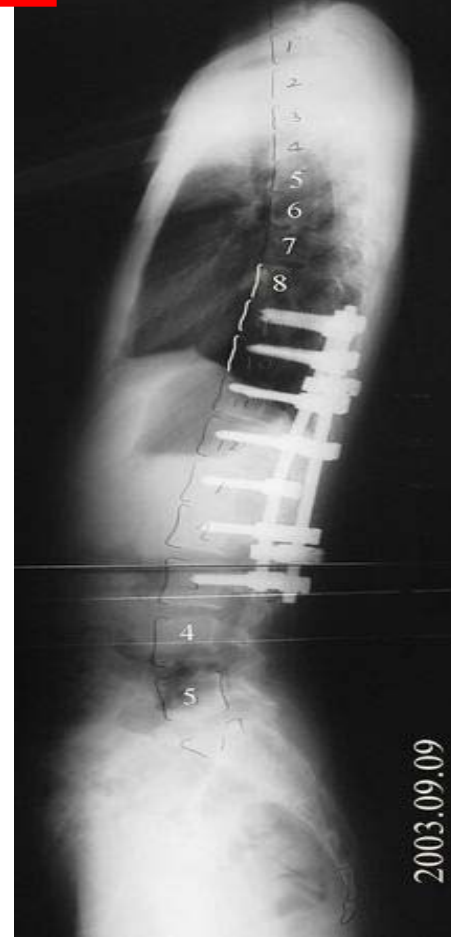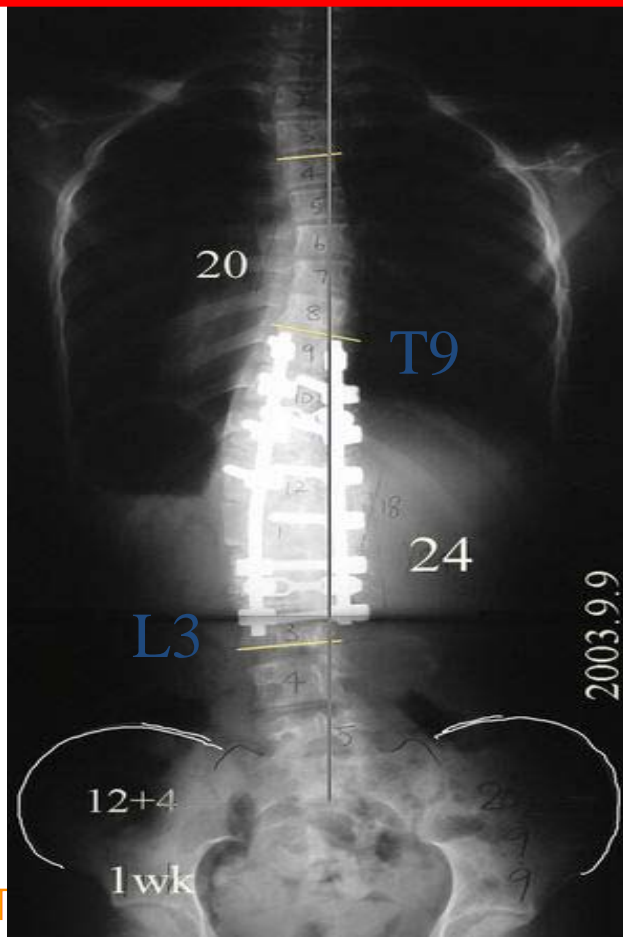
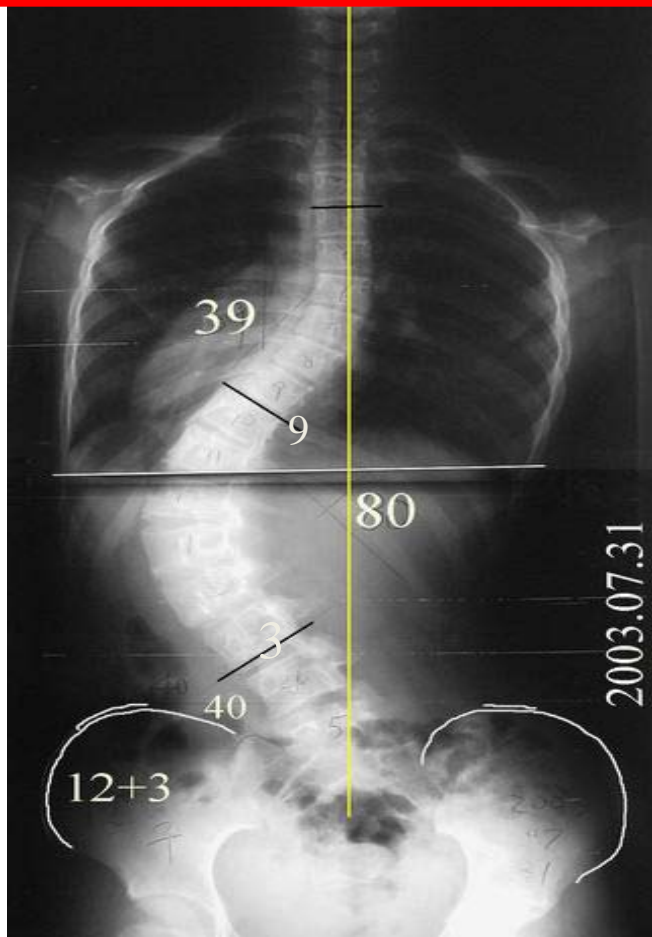
Similar gross appearance:

\*R't shoulder drop

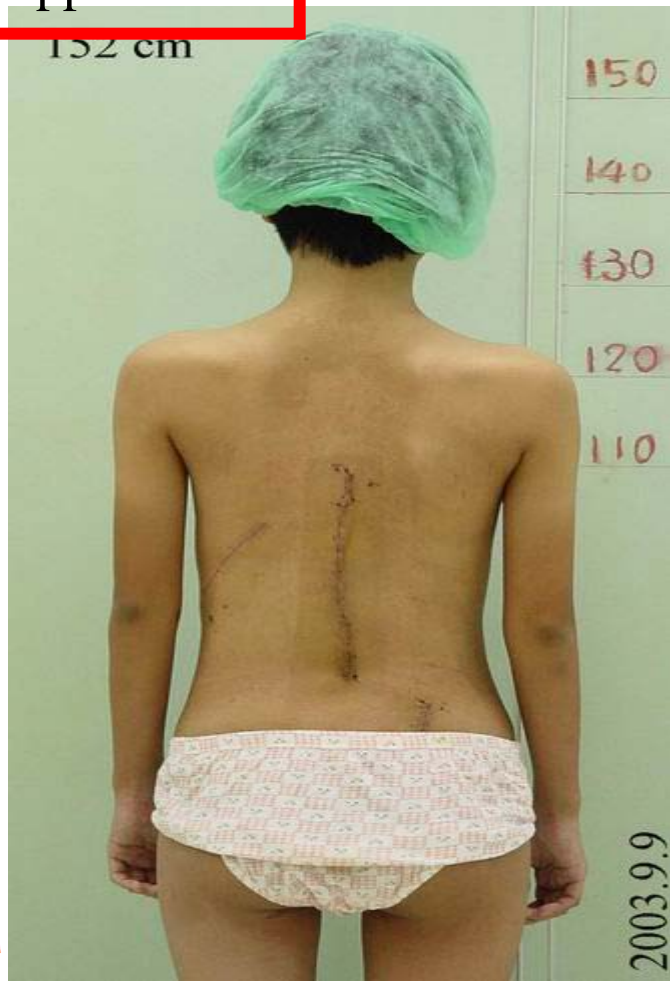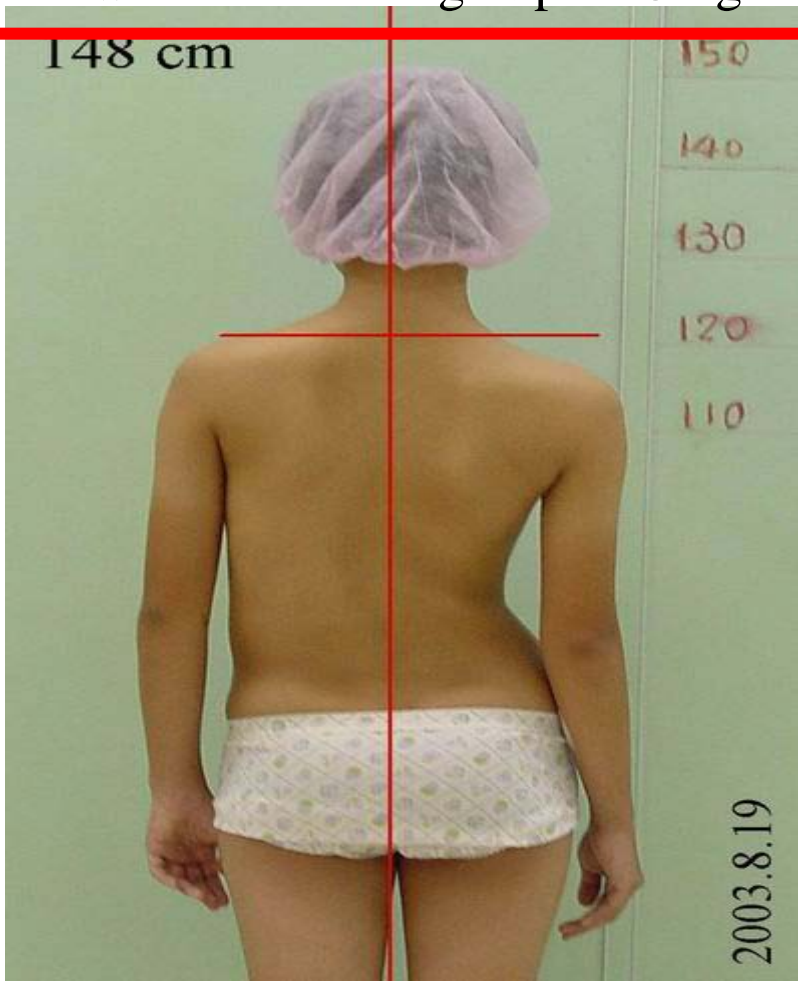
\*asymmetric waist line



The woman on the right: high Cobb angle with high deformity



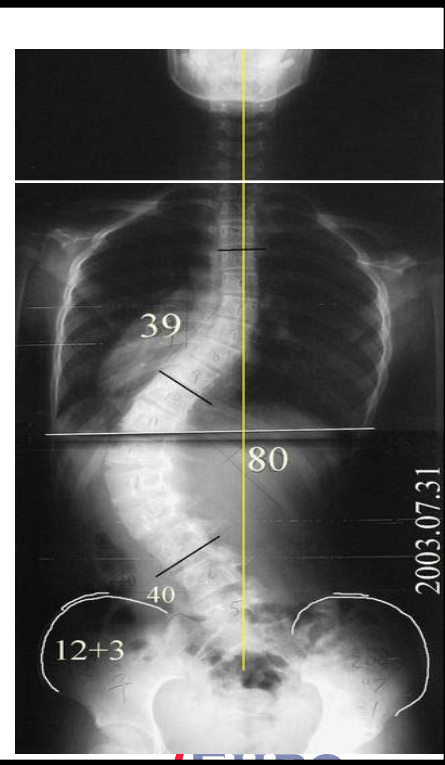
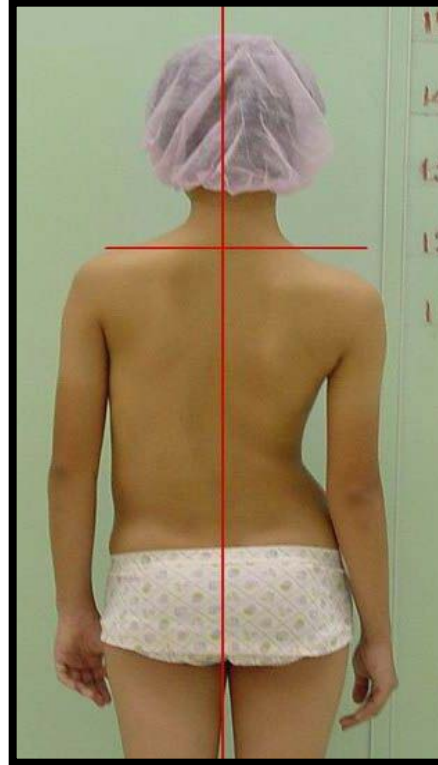
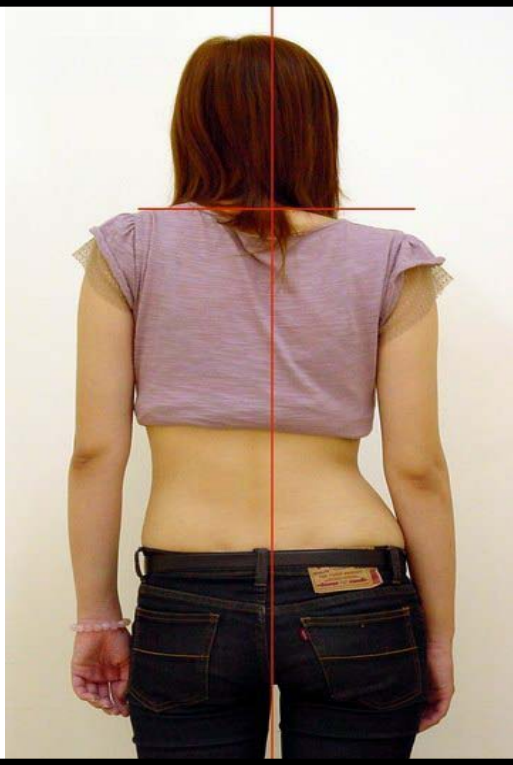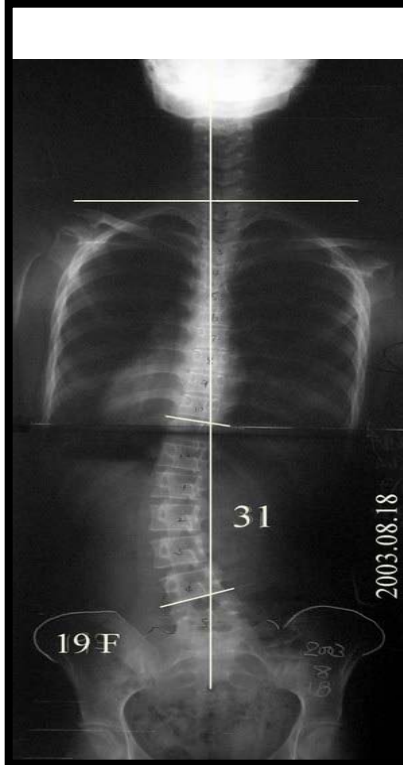
The woman on the right: post OP gross appearance





# Deformity $\neq$ Cobb angle

Similar gross appearance with big different Cobb angles

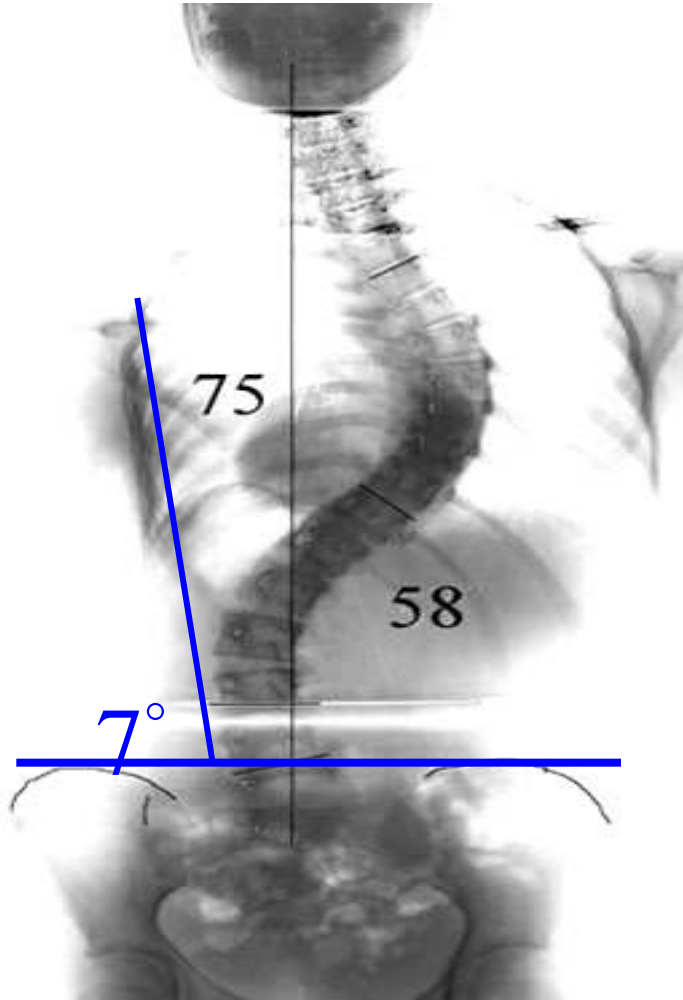
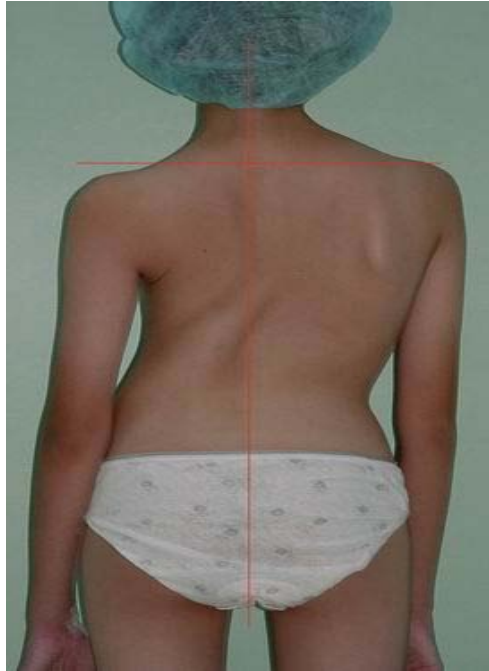

# Trunk Asymmetry Score

- Rib cage tilt
- Thoracic shift
- Thoracic containment
- Shoulder drop
- Hump height
- Axial inclination (rib hump angle)



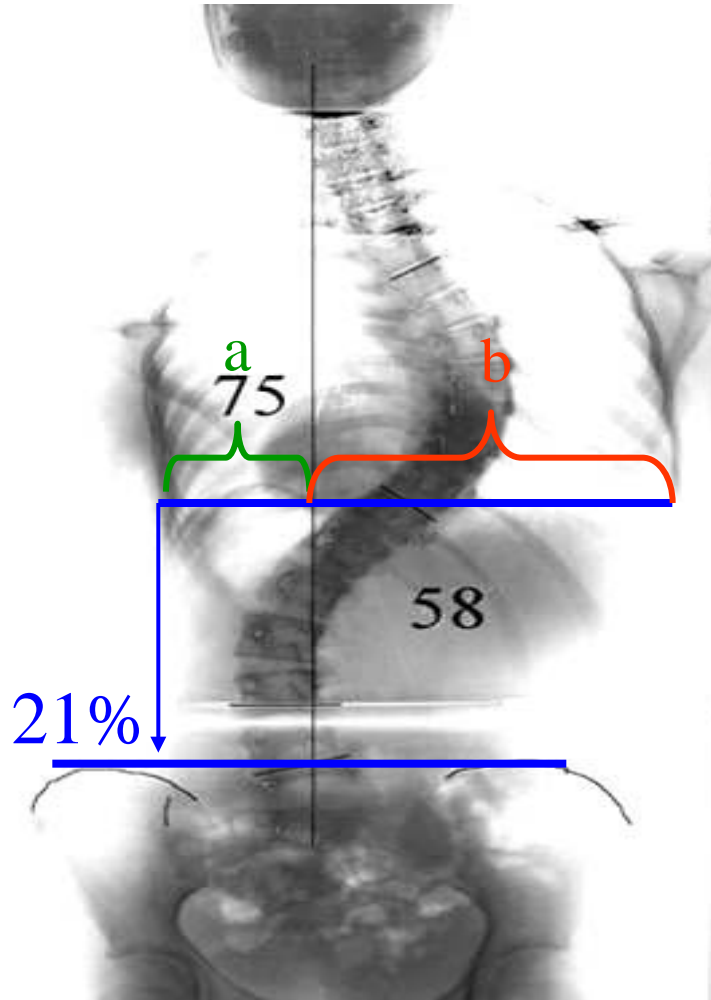
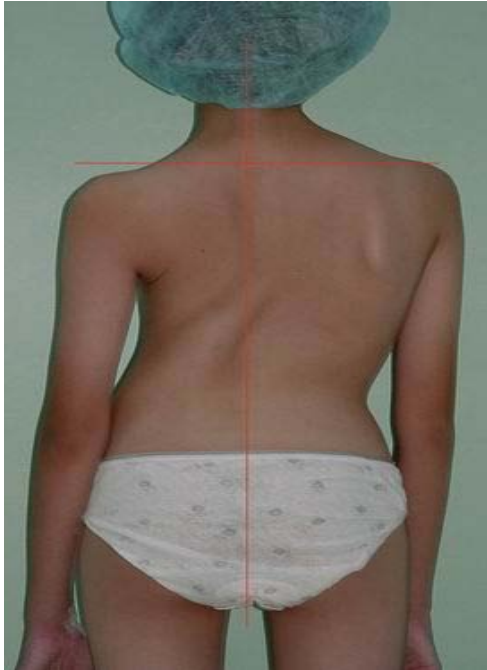



# Rib Cage Tilt

Angle from the vertical

Should be 0°

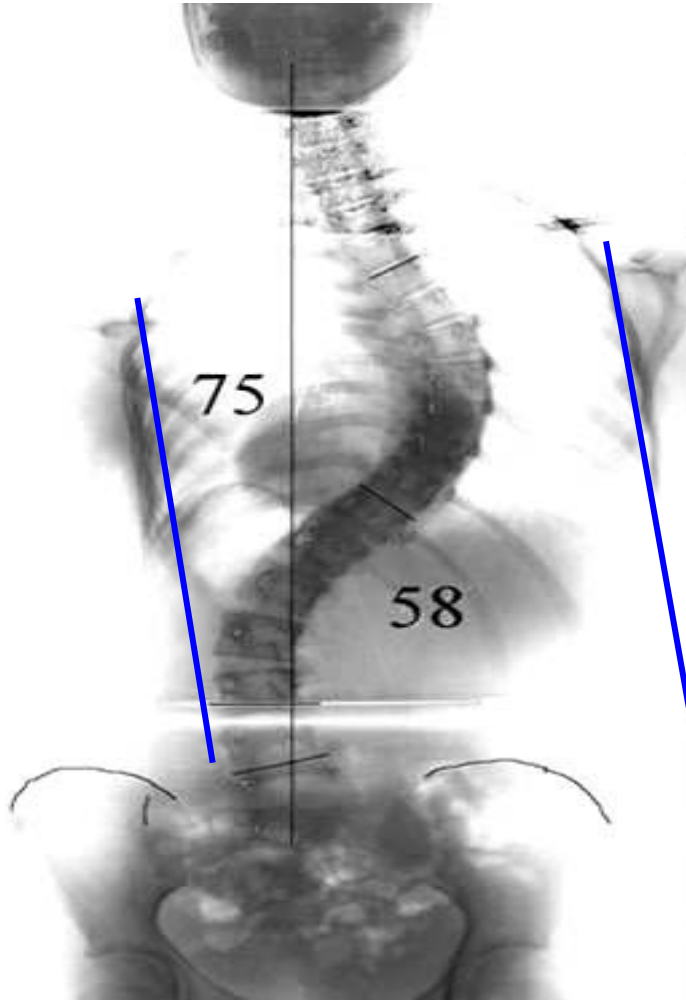


## 2. Thoracic Shift

Widest point

$$\% = \frac{(b-a)}{2(a+b)}$$

Should be 0%

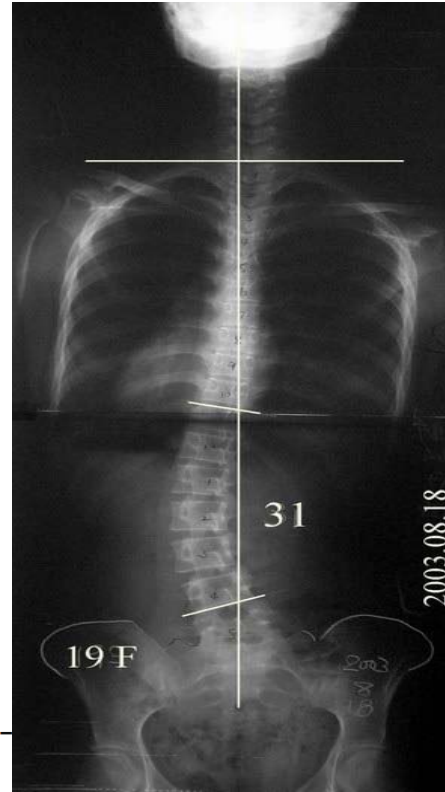
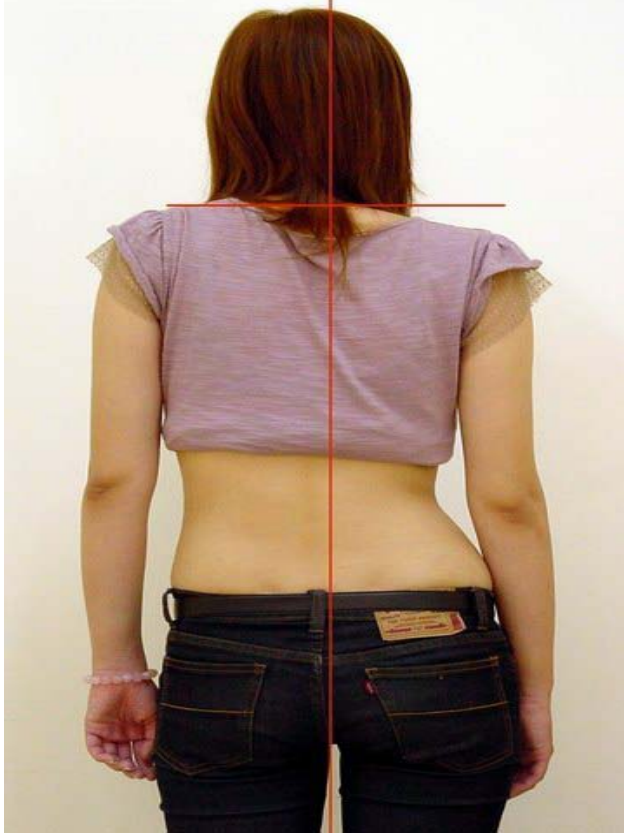

Thoracic  
Containment

Not Contained

# Why shouldn't I operate on her?

- for low Cobb angle with high deformity



SPINEWEEK

AY -

